

# Treatment of Partial-Thickness Rotator Cuff Tears With a Resorbable Bioinductive Bovine Collagen Implant

## 1-Year Results From a Prospective Multicenter Registry

Brandon D. Bushnell,<sup>\*†</sup> MD, MBA, Shariff K. Bishai,<sup>‡</sup> DO, Ryan J. Krupp,<sup>§</sup> MD, Sean McMillan,<sup>||</sup> DO, Brian A. Schofield,<sup>¶</sup> MD, Scott W. Trenhaile,<sup>#</sup> MD, and Louis F. McIntyre,<sup>\*\*</sup> MD

*Investigation performed at 19 participating centers of the REBUILD Registry*

**Background:** Surgical treatment of partial-thickness rotator cuff tears remains challenging and controversial, with several traditional options including debridement with acromioplasty, transtendon or in situ repair, and take-down and repair. A resorbable bioinductive bovine collagen implant has shown promise as an alternative treatment option for partial-thickness tears.

**Purpose:** Data from a registry were analyzed to further establish that the implant contributes to improved patient-reported outcome (PRO) scores across a large number of patients treated for partial-thickness rotator cuff tears.

**Study Design:** Case series; Level of evidence, 4.

**Methods:** A total of 19 centers in the United States enrolled patients >21 years old with partial-thickness tears of the rotator cuff in a comprehensive prospective multicenter registry. PRO scores were recorded preoperatively and postoperatively at 2 and 6 weeks, 3 and 6 months, and 1 year: American Shoulder and Elbow Surgeons, Single Assessment Numeric Evaluation, Veterans RAND 12-Item Health Survey (physical and mental component scores), and Western Ontario Rotator Cuff scores. Revisions were reported throughout the study.

**Results:** The registry included 272 patients with partial-thickness tears (49 grade 1 tears, 101 grade 2 tears, and 122 grade 3 tears), 241 who underwent isolated bioinductive repair (IBR; collagen implant placed after bursectomy without a traditional rotator cuff repair), and 31 who had take-down and repair with bioinductive augmentation. Patients experienced statistically significant and sustained improvement from baseline for all PRO scores beginning at 3 months. Among patients with grade  $\geq 2$  tears, those with take-down and repair had significantly inferior scores at 2 and 6 weeks for most PRO scores as compared with those who underwent IBR, but the difference was no longer significant at 1 year for all but the physical component score of the Veterans RAND 12-Item Health Survey. There were 11 revisions, which occurred at a mean  $\pm$  SD of  $188.7 \pm 88.0$  days after the index surgery. There were no infections.

**Conclusion:** This registry analysis further establishes across a large data set that this resorbable bioinductive bovine collagen implant improves PROs in all grades of partial-thickness tears, whether used as IBR or in conjunction with take-down and repair. IBR may offer improved early clinical outcomes ( $\leq 6$  weeks) and comparable outcomes at 1 year when compared with a more invasive “take-down and repair” approach.

**Keywords:** resorbable bioinductive bovine collagen implant; partial thickness; rotator cuff repair; take-down and repair; isolated bioinductive repair

Partial-thickness tears of the rotator cuff remain a treatment challenge. Nonoperative management often succeeds,<sup>14,28,32</sup> but in cases of failed conservative treatment, surgical management controversies abound. Surgeons are faced with a

choice: perform a debridement with subacromial decompression in hopes that the cuff will then heal as a result, or complete the tear and perform a repair as if it were a full-thickness lesion.<sup>10</sup> Transtendinous and in situ repair techniques were developed as a compromise of sorts between debridement and take-down and repair, with varied results.<sup>20,41</sup> More recently, as the biologics revolution has progressed in sports medicine, reports have

The Orthopaedic Journal of Sports Medicine, 9(8), 23259671211027850  
DOI: 10.1177/23259671211027850  
© The Author(s) 2021

This open-access article is published and distributed under the Creative Commons Attribution - NonCommercial - No Derivatives License (<https://creativecommons.org/licenses/by-nc-nd/4.0/>), which permits the noncommercial use, distribution, and reproduction of the article in any medium, provided the original author and source are credited. You may not alter, transform, or build upon this article without the permission of the Author(s). For article reuse guidelines, please visit SAGE's website at <http://www.sagepub.com/journals-permissions>.

appeared involving platelet-rich plasma, mesenchymal stem cells, scaffolds, and other options that attempt to help partial-thickness tears heal or at least prevent further progression.<sup>2,8,29,30,36,51,54</sup>

Promising results have been cited in several studies involving a resorbable bioinductive bovine collagen implant (REGENETEN; Smith & Nephew) designed for use in rotator cuff repairs.<sup>1,5,6,34,44,48,49</sup> Histologic analysis has shown induction of tendon formation in animal<sup>49</sup> and human<sup>1</sup> studies. Clinical studies have evaluated the implant in full- and partial-thickness tears.<sup>1,5,6,34,44</sup> The 2 largest studies of partial-thickness tear repairs reported that the implant had an excellent safety profile and led to significant improvements in clinical outcomes, yet they analyzed relatively small groups of patients (n = 33 and 90).<sup>34,44</sup>

A comprehensive multicenter registry was established to learn how surgeons utilize the implant, the indications in which it is most used in real-world practice, and how these practice patterns affect real-world outcomes. Our hypothesis was that isolated bioinductive repair (IBR; collagen implant placed after bursectomy without a traditional rotator cuff repair) would result in improved patient-reported outcome (PRO) scores for patients with partial-thickness rotator cuff tears, with a low rate of complications. The secondary purpose was to analyze the effect of various demographic, biologic, and surgical risk factors on outcomes—in particular, the performance of IBR with the implant alone in comparison with take-down and repair with implant supplementation in partial-thickness tears.

## METHODS

The multicenter REBUILD Registry (Rotation Medical Bioinductive Implant Database; Smith & Nephew) was created to track outcomes of surgical repairs using the resorbable bioinductive bovine collagen implant. Patients were

enrolled between April 2016 and December 2018 at 19 centers across the United States (see Acknowledgment). To be enrolled in the registry, patients had to be at least 21 years of age; able and willing to provide voluntary informed consent to participate in the registry; and able to read, speak, and understand English. They also had to have partial-thickness tears of the rotator cuff. Patients were excluded from the registry if they had known hypersensitivity to bovine-derived products. This study was performed in compliance with the ethical principles of the Declaration of Helsinki, and the study protocol received institutional review board approval. The protocol called for a registry goal enrollment of 500 patients.

According to registry protocol, formal prospective data collection occurred at the baseline preoperative visit, the operation itself, and postoperatively at 2 weeks, 6 weeks, 3 months, 6 months, and 1 year. Demographic data and medical history collected at baseline included patient age, sex, body mass index, history of diabetes, smoking status, involvement in workers' compensation claims, timing of injury, trauma association, duration of symptoms, nonsteroidal anti-inflammatory drugs, physical therapy, injections, and prior surgery. Surgical data comprised the Ellman classification<sup>15</sup> of the partial-thickness tear: grade 1, compromising <3 mm of tendon thickness (<25%); grade 2, having a depth of 3 to 6 mm (25%-50%); and grade 3, tears extending >6 mm in depth (>50%). Any concomitant procedures performed were also recorded. The involved tendon, tear type and specific location, and number of tears per case were not recorded. The following PROs were assessed at baseline and all follow-up points: American Shoulder and Elbow Surgeons (ASES; pain, shoulder function, and shoulder score), Single Assessment Numeric Evaluation (SANE), Veterans RAND 12-Item Health Survey (VR-12) physical and mental component scores (PCS and MCS), and Western Ontario Rotator Cuff (WORC). Recovery outcomes were assessed by cumulative days that the index shoulder was

\*Address correspondence to Brandon D. Bushnell, MD, MBA, Harbin Clinic Orthopedics, 1825 Martha Berry Blvd NW, Rome, GA 30165, USA (email: brad.bushnell.md@gmail.com) (Twitter: @RomeShoulderDoc).

†Department of Orthopedic Surgery, Harbin Clinic, Rome, Georgia, USA.

‡Associated Orthopedists of Detroit, Detroit, Michigan, USA.

§Norton Orthopedic Institute, Louisville, Kentucky, USA.

||Virtua Medical Center, Burlington, New Jersey, USA.

¶Schofield, Hand, and Bright Orthopaedics, Sarasota, Florida, USA.

\*Orthollinois, Rockford, Illinois, USA.

\*\*Orthopedic Partners, Nashville, Tennessee, USA.

Final revision submitted December 6, 2020; accepted January 12, 2021.

One or more of the authors has declared the following potential conflict of interest or source of funding: The article-processing charge for this study was provided by Smith & Nephew. B.D.B. has received research funding, consulting fees, and speaking fees from Smith & Nephew. S.K.B. has received research funding from Smith & Nephew; consulting fees from Arthrex, ArthroSurface, Ceterix, Davol, Medical Device Business Services, Smith & Nephew, Trice Medical, and Wright Medical; and speaking fees from Arthrex, Davol, Pacira Pharmaceuticals, Pinnacle, Smith & Nephew, and Zimmer Biomet. R.J.K. has received research funding from Smith & Nephew and Zimmer Biomet; education payments from Alpha Orthopedic Systems; consulting fees from Ignite Orthopedics, Medical Device Business Services, Smith & Nephew, Stryker, and Zimmer Biomet; and speaking fees from DJO, Encore Medical, Stryker, and Zimmer Biomet. S.M. has received consulting fees from Arthrex, Artos, BD/BARD, Ethicon US, Exactech, Medical Device Business Services, Pacira Pharmaceuticals, Smith & Nephew, Trice Medical, and Zimmer Biomet; speaking fees from Arthrex and Flexion Therapeutics; royalties from Trice Medical; honoraria from Davol; and hospitality fees from Liberty Surgical. S.M. also has stock/stock options in Artos. B.A.S. has a family member who is an employee of Smith & Nephew. B.A.S. also has received research funding from Arthrex, Smith & Nephew, and Stryker; consulting fees from FH Orthopedics; honoraria from Encore Medical; and royalties from FH Orthopedics. S.W.T. has received research funding, consulting fees, speaking fees, and royalties from Smith & Nephew and consulting fees and speaking fees from Exactech and Xiros. L.F.M. has received educational support from Arthrex; consulting fees from Active Implants, Ceterix, Embody, Flexion Therapeutics, Medical Device Business Services, Mininvasive, Smith & Nephew, and Zimmer Biomet; speaking fees from Smith & Nephew and Sanofi-Aventis; and royalties from Embody. AOSSM checks author disclosures against the Open Payments Database (OPD). AOSSM has not conducted an independent investigation on the OPD and disclaims any liability or responsibility relating thereto.

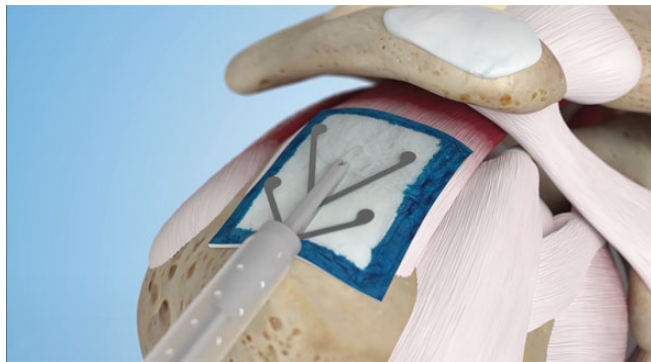
Ethical approval for this study was obtained from Western Institutional Review Board (protocol No. 20160611).

in a sling, completed physical therapy visits to rehabilitate the index shoulder, return to work (employed patients only), return to driving, and return to overhead throwing and non-overhead throwing sports. The number and percentage of patients who experienced a postoperative revision surgery were documented. Routine postoperative imaging was not obtained. Security protections were put in place so that each study center could access, enter, and view its own data and not those of the other participating centers.

Of 482 patients enrolled in the REBUILD registry, 272 had partial-thickness tears and 210 had full-thickness tears. For purposes of this study, only the partial-thickness tear group was analyzed.

### Study Implant and Surgical Technique

The study implant consists of 3 components: a bioinductive implant made from highly purified reconstituted collagen fibers derived from bovine tendon and designed to completely resorb within 6 months; polylactic acid (PLDLA) tendon anchors designed to functionally degrade by 6 months and completely resorb within 12 months; and polyetheretherketone (PEEK) bone anchors that are not resorbable.



**Figure 1.** Placement of the implant with the single-use disposable device. Image provided courtesy of Smith & Nephew.

The surgical technique for implantation of the resorbable bovine collagen implant has been described previously<sup>5,34,42</sup> but is summarized again here for convenience.

After informed consent for surgery was obtained, patients were placed under general anesthesia with an optional nerve block at the discretion of the treating surgeon. Patients could be then placed into the beach-chair or lateral decubitus position—again at the discretion of the treating surgeon. Diagnostic arthroscopy was performed, during which the surgeon confirmed the presence of a partial-thickness tear of the rotator cuff. Tears were classified by the Ellman system,<sup>15</sup> and chondral defect size (if present) was recorded. Rotator cuff surgical procedures were recorded, as were acromioplasty, acromioclavicular joint resection, biceps tenotomy or tenodesis, labral repair, capsular release, and tissue debridement. The periosteum lateral to the footprint was debrided to improve implantation.

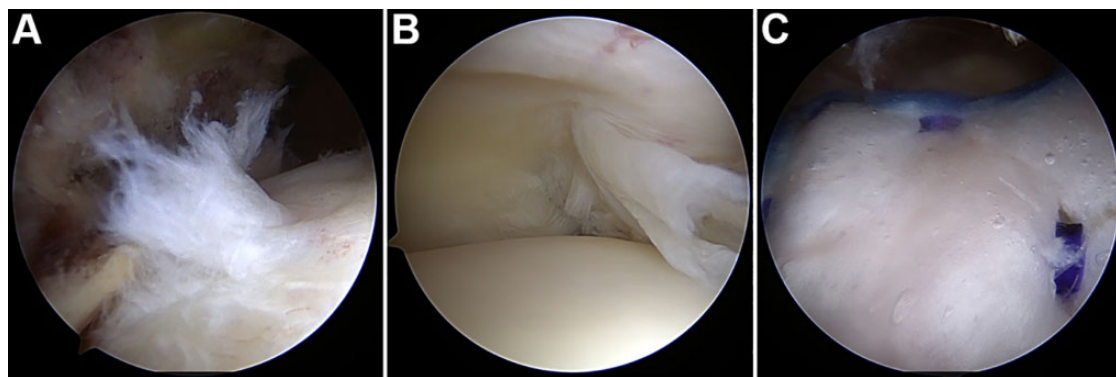
Surgeons selected from 2 implant sizes (20 × 25 mm [medium] or 25 × 30 mm [large]) to cover the tear and width of the supraspinatus tendon. The implant was then deployed in the subacromial space with a proprietary single-use disposable device (Figure 1). The implant was secured to the tendon using PLDLA tendon anchors and to the bone using PEEK bone anchors (Figure 2). Portals were then closed using standard methods.

Treatment of the partial-thickness tear was left to the discretion of the surgeon. If deemed appropriate, patients could undergo IBR in which the implant was placed after a bursectomy without a traditional rotator cuff repair. Conversely, tears could be treated with take-down and repair and then augmented with the implant.

A postoperative rehabilitation program, which has been described in the literature,<sup>34</sup> was applied to all patients with partial-thickness tears. This could be modified per surgeon preference in patients who underwent biceps surgery and/or take-down and repair.

### Statistical Analysis

Descriptive statistics were used to summarize patient demographic data, intraoperative surgical assessments,



**Figure 2.** (A) Bursal- and (B) articular-sided views of a hybrid high-grade partial-thickness tear treated with (C) isolated bioinductive repair using the resorbable bovine collagen implant.

and patient recovery outcomes. Means and standard deviations were calculated for each primary PRO at baseline and each follow-up visit, as well as for postoperative recovery parameters. The minimal clinically important difference (MCID) was calculated for the ASES, SANE, VR-12 MCS, VR-12 PCS, and WORC scores using established literature.<sup>12,18,55</sup> Continuous variables were reported as mean and standard deviation, and categorical variables were reported as the number and percentage of patients. Ad hoc analyses were performed to compare PROs at all time points based on how patients received the implant (IBR vs take-down and repair) and between baseline and 1-year follow-up for prior shoulder surgery, biceps surgery, history of diabetes, smoking status, and involvement in workers' compensation claims. Paired *t* tests were performed to test the difference between the means of the follow-up and the baseline measurements. Analyses were done with SAS Version 9.4 (SAS Institute). Statistical significance was set at  $P < .05$ .

## RESULTS

We enrolled 272 patients with partial-thickness tears (146 male, 126 female; mean age,  $52.1 \pm 10.0$  years; mean body mass index,  $29.9 \pm 6.0$  kg/m<sup>2</sup>). There were 29 patients (10.7%) with diabetes, 27 (9.9%) who were smokers, and 21 (7.7%) involved in workers' compensation claims. Patients experienced preoperative symptoms for a mean of  $29.6 \pm 25.4$  months. Timing of the shoulder injury was acute (traumatic) in 64 patients (23.5%), chronic in 164 (60.3%), and acute on chronic in 44 (16.2%). Preoperative duration of symptoms in the affected shoulder was  $11.9 \pm 33.2$  months in the acute group,  $31.2 \pm 54.1$  months in the chronic group, and  $31.2 \pm 42.5$  months in the acute-on-chronic group. There were 220 patients (80.9%) who reported taking nonsteroidal anti-inflammatory drugs, 196 (72.1%) who received injections, and 170 (62.5%) who underwent preoperative physical therapy. An additional 27 patients (9.9%) had undergone prior shoulder surgery.

Upon arthroscopic inspection, 49 patients (18.0%) had grade 1 tears, 101 (37.1%) had grade 2 tears, and 122 (44.9%) had grade 3 tears. A total of 31 patients (11.4%) had their tears completely and surgically repaired (1 grade 2 tear, 30 grade 3 tears), whereas the remaining 241 (88.6%) underwent IBR with the implant. Overall, 194 patients received medium implants, 75 large implants, 1 medium and large, and 2 had missing data. Concomitant procedures included acromioplasty in 258 patients (94.9%), acromioclavicular joint resection in 126 (46.3%), biceps tenodesis in 114 (41.9%), biceps tenotomy in 23 (8.5%), labral repair in 15 (5.5%), capsular release in 37 (13.6%), and debridement in 163 (59.9%).

One-year follow-up data were available for 227 patients (201 IBR, 26 take-down and repair) for an 83.5% follow-up rate. Reasons for discontinuation were as follows: lost to follow-up (36 patients), patient withdrew consent (4), patient withdrawn by investigator (1), patient not compliant (1), and other (3). For available patients, the mean study follow-up was  $382 \pm 83.7$  days.

## Clinical Outcomes and Recovery

There were significant improvements for all PROs between baseline and 1-year follow-up (Table 1). By 3 months, all PROs were significantly improved over baseline with the exception of VR-12 PCS, which became significant at 1 year. Score improvements met or exceeded the MCID at 1 year for 93.1% of patients for ASES, 91.6% for SANE, 33.9% for VR-12 MCS, 80.2% for VR-12 PCS, and 93.3% for WORC.

Patients with high-grade tears (grade  $\geq 2$ ) who underwent IBR had significantly better ASES Shoulder, SANE, and WORC scores at 2 and 6 weeks postoperative as compared with those who underwent take-down and repair. By 3 months, only scores on the SANE and VR-12 PCS remained significantly higher in the IBR group. At 1 year, there was no significant difference in PROs between the IBR and take-down groups, with the exception of the VR-12 PCS favoring the IBR group (48.6 vs 44.1;  $P = .0213$ ).

There was no statistically significant difference between baseline scores for those who had and had not undergone prior shoulder surgery. However, at 1 year, patients who had not undergone prior shoulder surgery had significantly superior scores for ASES Pain (0.9 vs 2.9;  $P < .0001$ ), ASES Function (26.6 vs 21.0;  $P = .0002$ ), ASES Shoulder (87.7 vs 71.0;  $P < .0001$ ), and WORC (85.2 vs 67.1;  $P = .0006$ ).

At 1 year, there was no significant differences in any scores between those who did and did not undergo concomitant biceps surgery and/or acromioclavicular joint resection, including when the analysis was confined to those with grade  $\geq 2$  tears.

Additional subgroup analyses indicated significant differences at 1 year for PROs based on demographic factors. Patients with diabetes had significantly lower scores on the VR-12 PCS (42.1 vs 49.4;  $P = .0001$ ) and WORC (72.7 vs 85;  $P = .0114$ ) than those without diabetes. Patients who smoked had significantly lower scores on the SANE (78.0 vs 87.0;  $P = .035$ ) and VR-12 PCS (44.7 vs 49.0;  $P = .0402$ ) than those who did not smoke. Patients involved in a workers' compensation claim had significantly inferior scores on the ASES Pain (2.3 vs 1.0;  $P = .0074$ ), ASES Shoulder (75.8 vs 88.9;  $P = .0254$ ), SANE (74.5 vs 87.2;  $P = .0043$ ), VR-12 MCS (50.6 vs 55.1;  $P = .0344$ ), VR-12 PCS (44.7 vs 49.0;  $P = .0478$ ), and WORC (66.2 vs 85.2;  $P = .0004$ ) than those who were not involved in such claims.

Patients reported a mean sling time of  $19.6 \pm 17.6$  days and a mean  $20.7 \pm 16.3$  days spent in formal physical therapy. In patients with grade 2 and 3 tears, those undergoing IBR indicated a significantly shorter mean sling time than those undergoing take-down and repair (19.1 vs 34.3 days;  $P < .0001$ ). For the recovery outcomes of the overall cohort, the mean time until return to work, driving, overhead throwing sports, and non-overhead throwing sports was  $33.3 \pm 48.4$ ,  $17.1 \pm 28.8$ ,  $123.5 \pm 76.8$ , and  $71.9 \pm 71.1$  days, respectively. In patients with grade 2 and 3 tears, there was no statistically significant difference in recovery outcomes in those treated with IBR versus take-down and repair, outside of an earlier return to nonoverhead sports for the IBR group (72.2 vs 128.9 days;  $P = .0192$ ). Other concomitant procedures, such as biceps tenodesis, labral repair, and

TABLE 1  
Patient-Reported Outcomes at Baseline and All Follow-up Points<sup>a</sup>

	ASES			SANE	VR-12		
	Pain	Shoulder Function	Shoulder Score		MCS	PCS	WORC
Baseline							
No.	270	197	197	270	213	213	248
Mean ± SD	5.5 ± 2.4	14.1 ± 6.2	46.8 ± 18.2	41.7 ± 19.9	51.9 ± 13.2	35.3 ± 8.4	36.4 ± 16.6
2 weeks							
No.	258	196	195	260	194	194	238
Mean ± SD	3.6 ± 2.6	7.8 ± 6.8	45.9 ± 18.5	35.3 ± 23.6	51.5 ± 12.2	33.9 ± 8.0	37.8 ± 16.7
P value	<b>&lt;.001</b>	<b>&lt;.001</b>	.894	<b>&lt;.001</b>	.932	<b>.041</b>	.13
6 weeks							
No.	257	195	195	257	190	190	221
Mean ± SD	2.9 ± 2.5	13.8 ± 7.3	59.9 ± 19.3	56.6 ± 20.4	52.5 ± 12.5	38.8 ± 7.5	50.3 ± 19.8
P value	<b>&lt;.001</b>	.796	<b>&lt;.001</b>	<b>&lt;.001</b>	.546	<b>&lt;.001</b>	<b>&lt;.001</b>
3 months							
No.	259	201	200	260	199	199	229
Mean ± SD	2.1 ± 2.4	18.9 ± 6.9	71.9 ± 20.5	69.9 ± 19.4	54.6 ± 12.0	43.1 ± 8.3	64.0 ± 22.6
P value	<b>&lt;.001</b>	<b>&lt;.001</b>	<b>&lt;.001</b>	<b>&lt;.001</b>	.174	<b>&lt;.001</b>	<b>&lt;.001</b>
6 months							
No.	233	172	170	235	188	188	212
Mean ± SD	1.5 ± 2.1	23.7 ± 6.4	82.7 ± 18.4	80.3 ± 18.7	54.2 ± 10.3	47.0 ± 8.6	76.8 ± 22.5
P value	<b>&lt;.001</b>	<b>&lt;.001</b>	<b>&lt;.001</b>	<b>&lt;.001</b>	.559	<b>&lt;.001</b>	<b>&lt;.001</b>
1 year							
No.	224	163	161	227	175	175	209
Mean ± SD	1.1 ± 2.0	26.1 ± 5.9	88.1 ± 17.9	86.2 ± 18.2	55.4 ± 8.9	49.2 ± 9.3	83.7 ± 21.7
P value	<b>&lt;.001</b>	<b>&lt;.001</b>	<b>&lt;.001</b>	<b>&lt;.001</b>	<b>.016</b>	<b>&lt;.001</b>	<b>&lt;.001</b>

<sup>a</sup>Bold *P* values indicate statistically significant difference vs baseline (*P* < .05). The number of patients at each time point for each score differs depending on how, when, and whether or not patients filled out all the recommended data collection forms. ASES, American Shoulder and Elbow Surgeons; MCS, mental component score; PCS, physical component score; SANE, Single Assessment Numeric Evaluation; VR-12, Veterans RAND 12-Item Health Survey; WORC, Western Ontario Rotator Cuff Index.

acromioclavicular joint resection, were not considered in this analysis owing to the limited sample size in the group undergoing take-down and repair.

### Revision Surgery

There were 11 surgical revisions in 10 patients (2 with grade 2 tears, 8 with grade 3 tears). Revisions occurred in 9 patients who received the implant as IBR (3.7%) and 1 patient (3.2%) as a supplement to take-down and repair. Reasons for revision (multiple answers possible) were shoulder stiffness/adhesive capsulitis (5 patients), clinically significant bursitis (3), retear/failure to heal (3), and dislodged graft (1). The mean time between index and revision surgery was 188.7 ± 88.0 days. There were no cases of infection or obvious immunologic “rejection” of the implant.

### DISCUSSION

Partial-thickness tears of the rotator cuff are a commonly encountered pathology in the shoulder, with a prevalence ranging from 13% to 33%.<sup>33</sup> Spontaneous healing of symptomatic partial-thickness tears is considered unlikely.<sup>16,17</sup> On the contrary, partial-thickness tears are at risk of further degenerating as a result of the substantial increased local intratendinous strain that they impart to the residual

intact tendon, particularly for those of grade ≥2.<sup>4,39,43,53</sup> Symptomatic tears typically present with pain, weakness, impaired function, and difficulties with overhead activities or sports.<sup>33,50</sup>

Although proper management of partial-thickness tears remains controversial, it is generally agreed that most patients should initially be treated with nonoperative interventions, such as rehabilitation, physical therapy, injections, and pain medications.<sup>47</sup> These interventions have been associated with clinical success, including 1 randomized trial in which patients with partial-thickness tears receiving nonoperative care had superior clinical outcomes to those undergoing immediate arthroscopic rotator cuff repair at 6 months.<sup>28</sup> However, such short-term clinical benefits may eventually be offset by the degenerative natural history of these tears, as demonstrated by studies reporting a substantial risk of progression to full-thickness tears within 1 to 3 years of nonoperative management.<sup>25,52</sup> Operative interventions (arthroscopic acromioplasty and rotator cuff debridement, subacromial decompression, transtendinous repair, and take-down and repair) have been noted to offer inadequate protective value at reducing tear progression and have limited ability to improve pain and function.<sup>3,7,9,21-24,26,27,37,45</sup>

The resorbable bioinductive bovine collagen implant employed in this registry analysis potentially addresses several limitations of the existing therapies for partial-thickness

tears. The implant is designed to maintain the native tendon and anatomic footprint while promoting healing through new tissue growth.<sup>1</sup> The new tendon-like tissue may reduce strain and promote a natural healing response.<sup>1,5,49</sup> Previous reports of patients with partial-thickness tears treated with IBR with this implant have noted increases in mean tendon thickness of 2.0 to 2.2 mm and significant improvements in ASES and Constant-Murley scores at up to 2-year follow-up.<sup>5,44</sup>

The current study confirms the results observed in earlier analyses of partial-thickness tears,<sup>1,5,6,34,44</sup> with significant improvements between baseline and 1 year for all PRO scores obtained. More than 90% of patients met or exceeded the MCID at 1 year for ASES, SANE, and WORC scores.<sup>12,18,55</sup> These outcomes are in line with those after various surgical repair methods, although some overviews of this topic do not report findings with the SANE or WORC.<sup>33,46</sup> Biceps surgery—a common source of controversy in shoulder outcomes—did not appear to have an impact on PROs in our study, with no significant difference observed at 1 year between those who did and did not undergo biceps tenodesis/tenotomy. While we did not control for or specifically analyze pre- or intraoperative diagnoses involving the biceps or labrum, the lack of impact of biceps surgery on outcome seems to indicate that the primary pathology in this population was the rotator cuff rather than the bicipital complex.

This study provides the first dedicated subanalysis of patients with grade  $\geq 2$  partial-thickness tears who received the implant as a supplement to take-down and repair. These patients had significantly inferior ASES Shoulder, SANE, and WORC scores upon early follow-up when compared with those undergoing IBR, which is not unexpected given the more invasive nature of take-down surgery. However, by 1 year both groups experienced statistically comparable outcomes, with the exception of the VR-12 PCS. The analysis was confined to grade  $\geq 2$  tears because most surgeons are unlikely to perform take-down and repair of a grade 1 tear. We believed that limiting analysis to higher-grade tears was more indicative of those cases in which the implant will actually be used.

Take-down and repair have been proposed as a beneficial strategy in partial-thickness tears involving  $>50\%$  of the tendon.<sup>9,13,22,23,26,38</sup> Yet, the procedure risks damaging normal tissue; it permanently alters the natural anatomic footprint, with a resulting discrepancy in length-tension relationships after repair; and it may require prolonged rehabilitation.<sup>19,31,35</sup> Such concerns led to the development of the transtendinous repair techniques, which keep the lateral tendon intact and restore the medial portion of the tendon to the original footprint, although to date they have largely failed to provide superior clinical outcomes and may increase early postoperative pain and stiffness.<sup>7,21,27,37,45</sup>

Based on results of the subgroup analysis in the current study, IBR with this implant may offer something of a proverbial ideal “middle ground,” providing more substantive intervention than debridement while avoiding the relatively more invasive requirements of take-down and repair or in situ/transtendon techniques. However, further

randomized studies are required to elucidate this potential position for the implant in the list of treatment options.

Of the 227 patients available at 1-year follow-up, 10 (4.4%) had undergone revision in this study. Revision rates in repairs of partial-thickness tears have been comparatively understudied in the literature,<sup>33</sup> despite being twice as common as full-thickness tears.<sup>40</sup> We could identify no studies offering revision rates in partial-thickness tears in a comparably large population with a similar follow-up with either novel biologic interventions or traditional surgical repair. Cummins and Murrell<sup>11</sup> noted a 2-year revision rate of 6.1% after rotator cuff repair with suture anchors in patients for whom the underlying tear type at index surgery was not identified. Although an imperfect comparison, it nonetheless suggests that the revision rate in the current analysis is within range of that previously reported.

### Limitations

This study has several limitations. There was no control group to compare outcomes with existing therapeutic interventions for this tear type. Although the lack of a well-defined standard of care for partial-thickness tears would make choosing the optimal control group difficult, it would nonetheless be valuable for isolating the effects of the implant. For example, it would be of interest to compare outcomes for take-down and repair with versus without the implant or to compare the IBR technique versus subacromial decompression alone. There are also limitations from the registry design, which was intended as a real-world evidence capture activity. It employed minimal inclusion and exclusion criteria. This was done to reflect the patients encountered in real-world clinical practices but could play an unforeseen role in biasing the results. Another registry limitation was the lack of full-score data capture at every time point, attributed to incomplete form fulfillment by various patients.

The study did not call for the recording of tear location, tear type, or the number of tears, which may influence outcomes in partial-thickness tears, and magnetic resonance imaging assessments were not performed to correlate tendon healing/thickness with PROs. Additionally, the study was not powered for assessing specific outcomes, such as a single score or a single risk factor. Instead, data were extracted and analyzed in an ad hoc manner. Given the relatively large size of this patient population, it was thought that this does not diminish the ability of the analysis to gauge the implant's ability to produce clinically meaningful improvements in PROs over time. Findings from subgroup analyses, however, likely require a structured and controlled design to reduce the potential for bias and cofounders. Also, there is a chance of bias introduced by the surgeons having the ability to choose whether or not to take down the cuff and do a repair versus doing an IBR with the implant alone. We did not test for immunologic responses in those cases of inflammation or stiffness after surgery, wherein a potential negative “reaction” or “rejection” might have been involved. Prior histologic and clinical studies, however, have not shown any sort of

immunologic rejection, so analysis of it was not part of the study protocol. Last, the current study provides only 1-year follow-up data, which is reflective of the typical follow-up period in everyday clinical practice but may lack the scope of a 2-year window to assess outcomes.

## CONCLUSION

This registry analysis further establishes across a large data set that this resorbable bioinductive bovine collagen implant improves PROs in all grades of partial-thickness tears, whether used as IBR or in conjunction with take-down and repair. IBR may offer improved early clinical outcomes and comparable outcomes at 1 year as compared with a more invasive “take-down and repair” approach.

## ACKNOWLEDGMENT

The authors acknowledge the efforts of the investigators who enrolled and treated patients for this study: Michael Adams, MD (Jacksonville Orthopaedic Institute, Jacksonville, Florida, USA); Alan Barber, MD (Plano Orthopedic Sports Medicine & Spine Center, Plano, Texas, USA); Shariff K. Bishai, DO (Associated Orthopedists of Detroit PC, St Clair Shores, Michigan, USA); J.P. Bramhall, MD (Central Texas Sports Medicine & Orthopaedics, Bryan, Texas, USA); Brad Bushnell, MD (Harbin Clinic Orthopaedics & Sports Medicine Rome, Rome, Georgia, USA); Thomas Kovack, MD (Hand and Microsurgery Associates, Columbus, Ohio, USA); Ryan Krupp, MD (Norton Orthopedic Institute, Louisville, Kentucky, USA); Marc R. Labbe, MD (Bone & Joint Clinic of Houston, Houston, Texas, USA); Ferdinand Liotta, MD (Glenwood Orthopaedic Center, Glenwood Springs, Colorado, USA); Louis F. McIntyre, MD (Westchester Medical Pavilion, White Plains, New York, USA); Sean McMillan, MD (Lourdes Medical Associates, Burlington, New Jersey, USA); Mayo Noerdlinger, MD (Atlantic Orthopaedics & Sports Medicine, Portsmouth, New Hampshire, USA); Christopher O’Grady, MD (Andrews Sports Medicine & Orthopaedic Center, Gulf Breeze, Florida, USA); James Penna, MD, James Paci, MD (Stony Brook Orthopaedics, Setauket, New York, USA); Charles Roth, MD (Andrews Research & Education Foundation, Gulf Breeze, Florida, USA); Benjamin Rubin, MD (Orthopaedic Specialty Institute, Orange, California, USA); Brian Schofield, MD (Schofield, Hand and Bright Orthopaedics, Sarasota, Florida, USA); Scott Sigman, MD (Orthopaedic Surgical Associates, North Chelmsford, Massachusetts, USA); and Scott Trenhaile, MD (OrthoIllinois Ltd, Rockford, Illinois, USA). The authors also thank John Watson and Cristin Taylor for their assistance with manuscript preparation.

## REFERENCES

1. Arnoczky SP, Bishai SK, Schofield B, et al. Histologic evaluation of biopsy specimens obtained after rotator cuff repair augmented with a highly porous collagen implant. *Arthroscopy*. 2017;33(2):278-283.

2. Bailey JR, Kim C, Alentorn-Geli E. Rotator cuff matrix augmentation and interposition: a systematic review and meta-analysis. *Am J Sports Med*. 2019;47(6):1496-1506.
3. Beard DJ, Rees JL, Cook JA, et al. Arthroscopic subacromial decompression for subacromial shoulder pain (CSAW): a multicentre, pragmatic, parallel group, placebo-controlled, three-group, randomised surgical trial. *Lancet*. 2018;391(10118):329-338.
4. Bey MJ, Ramsey ML, Soslowsky LJ. Intratendinous strain fields of the supraspinatus tendon: effect of a surgically created articular-surface rotator cuff tear. *J Shoulder Elbow Surg*. 2002;11(6):562-569.
5. Bokor DJ, Sonnabend D, Deady L, et al. Evidence of healing of partial-thickness rotator cuff tears following arthroscopic augmentation with a collagen implant: a 2-year MRI follow-up. *Muscles Ligaments Tendons J*. 2016;6(1):16-25.
6. Bokor DJ, Sonnabend D, Deady L, et al. Preliminary investigation of a biological augmentation of rotator cuff repairs using a collagen implant: a 2-year MRI follow-up. *Muscles Ligaments Tendons J*. 2015;5(3):144-150.
7. Bollier M, Shea K. Systematic review: what surgical technique provides the best outcome for symptomatic partial articular-sided rotator cuff tears? *Iowa Orthop J*. 2012;32:164-172.
8. Chen X, Jones IA, Togashi R, Park C, Vangsness CT. Use of platelet-rich plasma for the improvement of pain and function in rotator cuff tears: a systematic review and meta-analysis with bias assessment. *Am J Sports Med*. 2020;48(8):2028-2041.
9. Chung SW, Kim JY, Yoon JP, Lyu SH, Rhee SM, Oh SB. Arthroscopic repair of partial-thickness and small full-thickness rotator cuff tears: tendon quality as a prognostic factor for repair integrity. *Am J Sports Med*. 2015;43(3):588-596.
10. Cordasco FA. Editorial commentary. The partial thickness rotator cuff tear: is acromioplasty without repair ever indicated? *Arthroscopy*. 2018;34(1):82-83.
11. Cummins CA, Murrell GA. Mode of failure for rotator cuff repair with suture anchors identified at revision surgery. *J Shoulder Elbow Surg*. 2003;12(2):128-133.
12. Cvetanovich GL, Gowd AK, Liu JN, et al. Establishing clinically significant outcome after arthroscopic rotator cuff repair. *J Shoulder Elbow Surg*. 2019;28(5):939-948.
13. Deutsch A. Arthroscopic repair of partial-thickness tears of the rotator cuff. *J Shoulder Elbow Surg*. 2007;16(2):193-201.
14. Edwards P, Ebert J, Joss B, Bhabra G, Ackland T, Wang A. Exercise rehabilitation in the non-operative management of rotator cuff tears: a review of the literature. *Int J Sports Phys Ther*. 2016;11(2):279-301.
15. Ellman H. Diagnosis and treatment of incomplete rotator cuff tears. *Clin Orthop Relat Res*. 1990;254:64-74.
16. Fukuda H. Partial-thickness rotator cuff tears: a modern view on Codman’s classic. *J Shoulder Elbow Surg*. 2000;9(2):163-168.
17. Fukuda H, Hamada K, Nakajima T, Tomonaga A. Pathology and pathogenesis of the intratendinous tearing of the rotator cuff viewed from en bloc histologic sections. *Clin Orthop Relat Res*. 1994;304:60-67.
18. Gagnier JJ, Robbins C, Bedi A, Carpenter JE, Miller BS. Establishing minimally important differences for the American Shoulder and Elbow Surgeons score and the Western Ontario Rotator Cuff Index in patients with full-thickness rotator cuff tears. *J Shoulder Elbow Surg*. 2018;27(5):e160-e166.
19. Ghodadra NS, Provencher MT, Verma NN, Wilk KE, Romeo AA. Open, mini-open, and all-arthroscopic rotator cuff repair surgery: indications and implications for rehabilitation. *J Orthop Sports Phys Ther*. 2009;39(2):81-89.
20. Ide J, Maeda S, Takagi K. Arthroscopic transtendon repair of partial-thickness articular-side tears of the rotator cuff: anatomical and clinical study. *Am J Sports Med*. 2005;33(11):1672-1679.
21. Jordan RW, Bentic K, Saithna A. Transtendinous repair of partial articular sided supraspinatus tears is associated with higher rates of stiffness and significantly inferior early functional scores than tear completion and repair: a systematic review. *Orthop Traumatol Surg Res*. 2018;104(6):829-837.
22. Kamath G, Galatz LM, Keener JD, Teefey S, Middleton W, Yamaguchi K. Tendon integrity and functional outcome after arthroscopic repair

- of high-grade partial-thickness supraspinatus tears. *J Bone Joint Surg Am.* 2009;91(5):1055-1062.
23. Karjalainen TV, Jain NB, Page CM, et al. Subacromial decompression surgery for rotator cuff disease. *Cochrane Database Syst Rev.* 2019; 1(1):CD005619.
  24. Kartus J, Kartus C, Rostgård-Christensen L, Sernert N, Read J, Perko M. Long-term clinical and ultrasound evaluation after arthroscopic acromioplasty in patients with partial rotator cuff tears. *Arthroscopy.* 2006;22(1):44-49.
  25. Keener JD, Galatz LM, Teefey SA, et al. A prospective evaluation of survivorship of asymptomatic degenerative rotator cuff tears. *J Bone Joint Surg Am.* 2015;97(2):89-98.
  26. Kim KC, Shin HD, Cha SM, Park JY. Repair integrity and functional outcome after arthroscopic conversion to a full-thickness rotator cuff tear: articular- versus bursal-side partial tears. *Am J Sports Med.* 2014;42(2):451-456.
  27. Kim YS, Lee HJ, Bae SH, Jin H, Song HS. Outcome comparison between in situ repair versus tear completion repair for partial thickness rotator cuff tears. *Arthroscopy.* 2015;31(11):2191-2198.
  28. Kim YS, Lee HJ, Kim JH, Noh DY. When should we repair partial-thickness rotator cuff tears? Outcome comparison between immediate surgical repair versus delayed repair after 6-month period of nonsurgical treatment. *Am J Sports Med.* 2018;46(5):1091-1096.
  29. Kim YS, Sung CH, Chung SH, et al. Does an injection of adipose-derived mesenchymal stem cells loaded in fibrin glue influence rotator cuff repair outcomes? A clinical and magnetic resonance imaging study. *Am J Sports Med.* 2017;45(9):2010-2018.
  30. Lamplot JD, Rodeo SA, Brophy RH. A practical guide for the current use of biologic therapies in sports medicine. *Am J Sports Med.* 2020; 48(2):488-503.
  31. Lo IKY, Burkhart SS. Transtendon arthroscopic repair of partial thickness, articular surface tears of the rotator cuff. *Arthroscopy.* 2004; 20(2):214-220.
  32. Maman E, Harris C, White L, Tomlinson G, Shashank M, Boynton E. Outcome of nonoperative treatment of symptomatic rotator cuff tears monitored by magnetic resonance imaging. *J Bone Joint Surg Am.* 2009;91(8):1898-1906.
  33. Matthewson G, Beach CJ, Nelson AA, et al. Partial thickness rotator cuff tears: current concepts. *Adv Orthop.* 2015;2015:458786.
  34. McIntyre LF, Bishai SK, Brown PB III, Bushnell BD, Trenhaile SW. Patient-reported outcomes after use of a bioabsorbable collagen implant to treat partial and full-thickness rotator cuff tears. *Arthroscopy.* 2019;35(8):2262-2271.
  35. Millett PJ, Wilcox RB III, O'Holleran JD, Warner JJ. Rehabilitation of the rotator cuff: an evaluation-based approach. *J Am Acad Orthop Surg.* 2006;14(11):599-609.
  36. Murthi AM, Lankachandra M. Technologies to augment rotator cuff repair. *Orthop Clin North Am.* 2019;50(1):103-108.
  37. Ono Y, Woodmass JM, Bois AJ, Boorman RS, Thornton GM, Lo IK. Arthroscopic repair of articular surface partial-thickness rotator cuff tears: transtendon technique versus repair after completion of the tear—a meta-analysis. *Adv Orthop.* 2016;2016:7468054.
  38. Porat S, Nottage WM, Fouse MN. Repair of partial thickness rotator cuff tears: a retrospective review with minimum two-year follow-up. *J Shoulder Elbow Surg.* 2008;17(5):729-731.
  39. Reilly P, Amis AA, Wallace AL, Emery RJ. Supraspinatus tears: propagation and strain alteration. *J Shoulder Elbow Surg.* 2003;12(2): 134-138.
  40. Resnick D, Kang HS, Pretterklieber ML. Shoulder. In: Resnick D, Kang HS, Pretterklieber ML, eds. *Internal Derangements of Joints.* Elsevier; 2007:713-1122.
  41. Rossi LA, Atala NA, Bertona A, et al. Long-term outcomes after in situ arthroscopic repair of partial rotator cuff tears. *Arthroscopy.* 2019; 35(3):698-702.
  42. Ryu RK, Ryu JH, Abrams JS, Savoie FH. Arthroscopic implantation of a bio-inductive collagen scaffold for treatment of an articular-sided partial rotator cuff tear. *Arthrosc Tech.* 2015;4(5):e483-e485.
  43. Sano H, Wakabayashi I, Itoi E. Stress distribution in the supraspinatus tendon with partial-thickness tears: an analysis using two-dimensional finite element model. *J Shoulder Elbow Surg.* 2006; 15(1):100-105.
  44. Schlegel TF, Abrams JS, Bushnell BD, Brock JL, Ho CP. Radiologic and clinical evaluation of a bioabsorbable collagen implant to treat partial-thickness tears: a prospective multicenter study. *J Shoulder Elbow Surg.* 2018;27(2):242-251.
  45. Shin SJ. A comparison of 2 repair techniques for partial-thickness articular-sided rotator cuff tears. *Arthroscopy.* 2012;28(1):25-33.
  46. Strauss EJ, Salata MJ, Kercher J, et al. The arthroscopic management of partial-thickness rotator cuff tears: a systematic review of the literature. *Arthroscopy.* 2011;27(4):568-580.
  47. Tashjian RZ. Epidemiology, natural history, and indications for treatment of rotator cuff tears. *Clin Sports Med.* 2012;31(4):589-604.
  48. Thon SG, O'Malley L II, O'Brien MJ, Savoie FH III. Evaluation of healing rates and safety with a bioinductive collagen patch for large and massive rotator cuff tears: 2-year safety and clinical outcomes. *Am J Sports Med.* 2019;47(8):1901-1908.
  49. Van Kampen C, Arnoczky S, Parks P, et al. Tissue-engineered augmentation of a rotator cuff tendon using a reconstituted collagen scaffold: a histological evaluation in sheep. *Muscles Ligaments Tendons J.* 2013;3(3):229-235.
  50. Vinanti GB, Rossato A, Scrimieri D, Petrera M. Arthroscopic transtendon repair of partial articular-sided supraspinatus tendon avulsion. *Knee Surg Sports Traumatol Arthrosc.* 2017;25(7):2151-2156.
  51. Yamamoto N, Mineta M, Kawakami J, Sano H, Itoi E. Risk factors for tear progression in symptomatic rotator cuff tears: a prospective study of 174 shoulders. *Am J Sports Med.* 2017;45(11): 2524-2531.
  52. Yamanaka K, Matsumoto T. The joint side tear of the rotator cuff: a followup study by arthrography. *Clin Orthop Relat Res.* 1994;304: 68-73.
  53. Yang S, Park HS, Flores S, et al. Biomechanical analysis of bursal-sided partial thickness rotator cuff tears. *J Shoulder Elbow Surg.* 2009;18(3):379-385.
  54. Yoon JP, Lee CH, Jun JW, et al. Sustained delivery of transforming growth factor B1 by use of absorbable alginate scaffold enhances rotator cuff healing in a rabbit model. *Am J Sports Med.* 2018;46(6): 1441-1450.
  55. Zhou L, Natarajan M, Miller BS, Gagnier JJ. Establishing minimal important differences for the VR-12 and SANE scores in patients following treatment of rotator cuff tears. *Orthop J Sports Med.* 2018;6(7):2325967118782159.